

Renal artery pseudoaneurysm

Pseudoaneurisma de artéria renal

Authors

Luiz Inácio Roman¹
 Cauana Fabrício Efel¹
 Victória Teles França¹
 Carolina Meert Merten¹
 Claus Dieter Dummer^{1,2}

¹ Universidade de Santa Cruz do Sul, Faculdade de Medicina, Santa Cruz do Sul - RS, Brazil.

² Hospital Santa Cruz, Santa Cruz do Sul - RS, Brazil.

ABSTRACT

The renal artery pseudoaneurysm embody a rare vascular complication coming of percutaneous procedures, renal biopsy, nephrectomy, penetrating traumas and more rarely blunt traumas. The clinical can be vary according the patient, the haematuria is the symptom more commom. Is necessary a high level of clinical suspicion for your diagnosis, this can be elucidated by through complementary exams as the eco-color Doppler and the computed tomography scan (CT). This report is a case of a patient submitted a right percutaneous renal biopsy and that, after the procedure started with macroscopic haematuria, urinary tenesmus and hypogastric pain. The diagnosis of pseudoaneurysm was given after one week of evolution when the patient was hospitalized because gross haematuria, tachycardia, hypotension and hypochondrium pain. In the angiotomography revealed a focal dilation of the accessory right renal inferior polar artery, dilation of renal pelvis and all the ureteral course with presence hyperdenso material (clots) inside the middle third of the ureter. The treatment for the majority of this cases are conservative, through arterial embolization, indicated for those of smaller dimensions in patients who are hemodynamically stable. However, it was decided by clinical treatment with aminocaproic acid 1 g, according to previous studies for therapy of haematuria. The patient received discharge without evidence of macroscopic haematuria and with normal renal ultrasound, following ambulatory care.

Keywords: hematuria; image-guided biopsy; renal artery.

RESUMO

O pseudoaneurisma de artéria renal constituiu-se de uma rara complicação vascular advinda de procedimentos percutâneos, biópsias renais, nefrectomia, traumas penetrantes e mais raramente traumas contusos. A clínica pode variar de acordo com cada paciente, sendo a hematúria o sintoma mais comum. Visto isso, é necessário um alto nível de suspeição clínica para seu diagnóstico, que pode ser elucidado através de exames complementares, como o Ecodoppler colorido e tomografia computadorizada. Neste relato, apresentamos o caso de um paciente submetido à biópsia renal direita percutânea e que, após o procedimento, iniciou com hematúria macroscópica, tenesmo urinário e dor em hipogástrico. O diagnóstico de pseudoaneurisma foi dado após uma semana de evolução, quando o paciente foi internado por hematúria franca, taquicardia, hipotensão e dor em hipocôndrio. Em angiotomografia, foi revelada uma dilatação focal da artéria renal polar acessória inferior à direita, dilatação da pelve renal e de todo trajeto ureteral, com presença de material hiperdenso (coágulos) no interior do terço médio do ureter. O tratamento de escolha para a maioria dos casos é conservador, através da embolização arterial, indicada para aqueles de menores dimensões em pacientes estáveis hemodinamicamente. Entretanto, optou-se inicialmente pelo tratamento clínico com ácido aminocapróico 1 g, com base nos estudos prévios para tratamento da hematúria. O paciente recebeu alta sem evidências de hematúria macroscópica e com ecografia renal normal, seguindo em acompanhamento ambulatorial.

Palavras-chave: artéria renal; biópsia guiada por imagem; hematuria.

Submitted on: 04/02/2017.

Approved on: 05/01/2017.

Correspondence to:

Luiz Inácio Roman.
 E-mail: roman_luiz@live.com

DOI: 10.5935/0101-2800.20170080

INTRODUCTION

Aneurysms are abnormal dilations of a blood vessel lumen, secondary to diseases or aggressions of the vascular wall. Depending on the involvement of the vascular layers, they can be classified into two types: true aneurysms and pseudoaneurysms. True aneurysms are dilatations with preservation of the three layers of the arterial wall - intima, medium and adventitia. Pseudoaneurysms are related to the lesion of one or more of the vascular layers.¹

The renal artery pseudoaneurysm (RAP) is a rare vascular complication, which is etiologically associated with partial nephrectomy, percutaneous procedures, renal biopsy, penetrating trauma and, more rarely, blunt trauma.¹⁻³ Among the causes, traumatic or iatrogenic are the most frequent.⁴ There are several complementary tests available for the diagnosis of this vascular lesion, such as Doppler ultrasonography, arteriography, angio-CT, renal scintigraphy and magnetic resonance imaging.^{2,3} Despite RAP being a rare complication stemming from factors such as renal biopsy, it bears unusual clinical detection and usually requires a high degree of clinical suspicion, since it is difficult to diagnose.³ Thus, this study is justified in order to better understand this rare vascular complication.

REPORT

A 50-year-old white male patient with systemic arterial hypertension and type 2 *diabetes mellitus* (DM2). He had a history of renal function loss (creatinine of 2.3 mg/dL and glomerular filtration rate of 29 mL/min/m²) and proteinuria (IPC 0.326 mg/dL), not matching the DM2 evolution. He was submitted to percutaneous right ultrasound-guided renal biopsy. After the procedure, the patient started with macroscopic hematuria, urinary tenesmus and hypogastrium abdominal pain. Ultrasound showed intravesical clots. A three-way bladder catheter was introduced, and local continuous irrigation was started. After 48 hours, cystoscopy was performed for the persistence of hematuria, evacuating the clots. During the procedure, no active bleeding was identified by the right ureteral meatus.

After 96 hours of hospitalization, the patient was discharged without hematuria. After one week, he resumed with overt hematuria, presenting at the

outpatient clinic with a blood pressure of 100/60 mmHg, tachycardic, pale and with pain upon hypogastric palpation. He was re-admitted, and an angio-CT was ordered, which revealed focal dilation of the inferior accessory right renal artery, attributed to the pseudoaneurysm (Figures 1 and 2), and in the late phase there was contrast remaining in the right kidney.

Figure 1. Angio-CT showing focal dilation of the accessory inferior renal right artery related to the pseudoaneurysm.

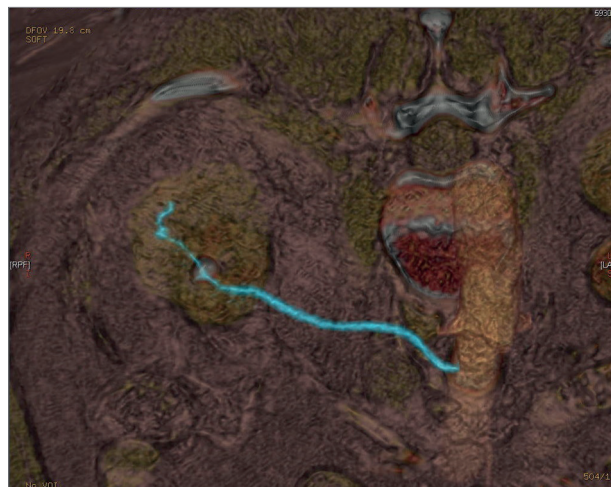
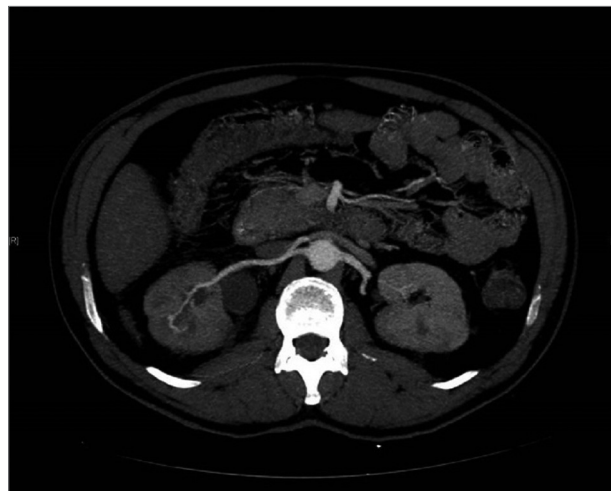

Figure 2. Abdominal CT with probable focal lesion of the right inferior accessory renal artery.



There was also a slight dilation of some tributary veins in the right renal sinus, dilation of the renal pelvis and the entire ureteral path up to just below the junction with the iliac vessels, with hyperdense material (clots) inside the medium third of the ureter. Then, 1 g of aminocaproic acid was started, 3 times per day. After 72 hours, the patient was discharged without evidence of macroscopic hematuria, with normal renal and urinary

tract echograms, without evidence of intravesical clots. He will be followed in an outpatient basis.

DISCUSSION

RAP is a rare vascular lesion.³ The pseudoaneurysm can be defined as a pulsatile hematoma that communicates with the artery through a small hole in the arterial wall.¹ Then, neck is formed, one that connects the artery to one or more cavities (which walls are formed by the tissue itself around the artery), allowing systolic flow towards the cavity and diastolic flow towards the artery, unlike the true aneurysm, whose walls are those of the vessel itself.¹

These vascular lesions are generally related to renal biopsy, nephrectomy, renal transplantation or percutaneous procedures.^{3,5} In addition, there is a relationship with penetrating traumas and, more rarely, with blunt traumas, the mechanism of sudden deceleration in automobile accidents is the most probable cause.³

Clinical manifestations of these lesions include: macroscopic hematuria, flank and lower back pain, hypertension and palpable abdominal mass.³ Hematuria is the symptom most commonly associated with RAP, and it is the result of the pseudoaneurysm erosion to the adjacent renal collection system.⁶ Renal function may get worse, evolving to anuria, and dialysis.³ Clinical signs may vary according to the patient, and it may worsen immediately after the insult or days to weeks later.⁶ Diagnosis of this type of injury is difficult and requires a high level of clinical suspicion, with complementary exams being an essential tool for diagnostic elucidation.^{5,7}

Therefore, when the patient is hemodynamically stable, non-invasive methods can be used.⁶ Among them, colorectal Doppler (CRD) has good diagnostic accuracy, as well as computed tomography (CT) and magnetic resonance imaging (MRI). However, the CRD performed by an experienced professional is the ideal method for the evaluation of pseudoaneurysms, since it bears low cost, it can be done at the bedside, it does not require contrast, and there are no restrictions on reproducibility. CT scans, on the other hand, require nephrotoxic contrast.⁷

Here RAP is best seen in the arterial phase, appearing as a high attenuation focal lesion with density similar to that of adjacent arterial vessels. The advantage of CT is the possibility of obtaining images of the entire urinary tract, being considered the technique of choice for follow-up.⁶ MRI uses non-nephrotoxic (gadolinium) contrast, but, like CT, it is costly and restricted to large hospital centers, being reserved for RAP located in areas of difficult access.⁷ Renal scintigraphy can also be used, but at a lower frequency.³

In cases where the aforementioned imaging exams are not conclusive and clinical suspicion of RAP remains, or in patients with hemodynamic instability, angiography is necessary. This is considered the gold standard for diagnosis, enabling confirmation, characterization of pseudoaneurysm and simultaneous endovascular management - with embolization presenting success rates above 90%.⁶ However, it is an invasive test that uses potentially nephrotoxic contrast and high cost.⁷

RAP must be part of the differential diagnosis of any patient with a history of trauma, surgery or renal biopsy, who develops flank pain and hematuria.³ Other differential pathologies should be considered, with arteriovenous fistula being the most important.^{8,9}

Regarding complications, one should consider the possibility of thromboembolism, infection, ruptured pseudoaneurysm and neurovascular compression.^{1,5,7,9} The risk of rupture is low, but it is associated with high mortality rates, reaching 80 % of cases.⁶ Another possible complication of pseudoaneurysms is the arterio-enteric fistulas, defined as a communication between an arterial vessel and the digestive system, which require immediate treatment.¹

Pseudoaneurysm treatment can be surgical or conservative, depending on the clinical signs of the patient. Nephrectomy and open vascular surgery are indicated in pseudoaneurysms greater than 2 cm, or when associated with complications such as severe hemorrhage and renovascular hypertension.⁶

The treatment of choice for most cases is conservative, through arterial embolization, indicated for those with smaller lesions, hemodynamically stable, although some authors have

demonstrated the therapeutic efficacy of embolization in aneurysms of up to 10 cm.^{3,5,7} However, the use of aminocaproic acid was initially chosen based on previous studies for the treatment of hematuria.^{10,11}

REFERENCES

1. Artech AH, Roman CA, Toro RM, Gomez PPA, González FS, Cabrera JAC. Pseudoaneurisma de artéria renal principal associado a fistula cecal trasnefrectomia radical: caso clínico y revisión de la literatura. *Sanid Mil* 2014;70:95-7.
2. Castillo CO, Díaz MJ, Caffarena AE, Díaz CM, Hoyos MJ. Pseudoaneurisma arteria renal postnefrectomía parcial: Tratamiento exitoso con embolización selectiva. *Rev Chil Cir* 2006;58:382-5. DOI: <http://dx.doi.org/10.4067/S0718-40262006000500013>
3. Melo RAV, Pires MJM, Silva LMS, Segóvia AB. Giant renal artery pseudoaneurysm 18 months after blunt trauma. *J Vasc Bras* 2013;12:159-62. DOI: <http://dx.doi.org/10.1590/S1677-54492013000200012>
4. Galego SJ, Barbato H, Corrêa JA, Kafajian O, Polimanti AC, Fürst RVC, et al. Pseudo-aneurisma de artéria renal pós-endopielotomia retrógrada: relato de caso e revisão de literatura. *J Vasc Br* 2004;3:285-7.
5. Pastorín R, Rodríguez N, Polo AM, Vicente JM, Luján M. Posttraumatic giant renal pseudoaneurysm. *Emerg Radiol* 2007;14:117-21. DOI: <http://dx.doi.org/10.1007/s10140-007-0573-5>
6. Yang HK, Koh ES, Shin SJ, Chung S. Incidental renal artery pseudoaneurysm after percutaneous native renal biopsy. *BMJ Case Rep* 2013;2013. pii: bcr2012006537. DOI: <http://dx.doi.org/10.1136/bcr-2012-006537>
7. Nogueira ACS, Salgado CG, Nogueira FBS, Amaral SI, Rabischoffsky A. Pseudoaneurisma: Quando e Como tratá-los. *Arq Bras Cardiol Imagem Cardiovasc.* 2013;26:289-307.
8. Dou C, Jin Y, Sun S, Zhou A, Chen X. Interventional treatment of post-biopsy renal artery pseudoaneurysm in a child: case report and literature review. *Zhonghua Er Ke Za Zhi* 2015;53:775-8.
9. Albani JM, Novick AC. Renal artery pseudoaneurysm after partial nephrectomy: three case reports and a literature review. *Urology* 2003;62:227-31. DOI: [http://dx.doi.org/10.1016/S0090-4295\(03\)00364-9](http://dx.doi.org/10.1016/S0090-4295(03)00364-9)
10. Elliott SJ, Salcedo JR. Hematuria after renal allograft biopsy: treatment with aminocaproic acid. *Urology* 1985;26:20-1. PMID: 3892850 DOI: [http://dx.doi.org/10.1016/0090-4295\(85\)90247-X](http://dx.doi.org/10.1016/0090-4295(85)90247-X)
11. Gaines KK. Aminocaproic acid (Amicar): potent antifibrolytic agent for treating hematuria. *Urol Nurs* 2003;23:156-8. PMID: 12778831